

# **Tumescent-augmented sclerotherapy: a new method in the treatment of large varicose veins**

**Saim Yılmaz, Kağan Çeken, Emel Alimoğlu, Timur Sindel**

**Department of Radiology, Akdeniz University School of Medicine,  
Antalya/Turkey**

The authors do not have any financial interest, consultancy or other relationship with product, manufacturer(s) of products or providers of services related to this abstract.



## **PURPOSE:**

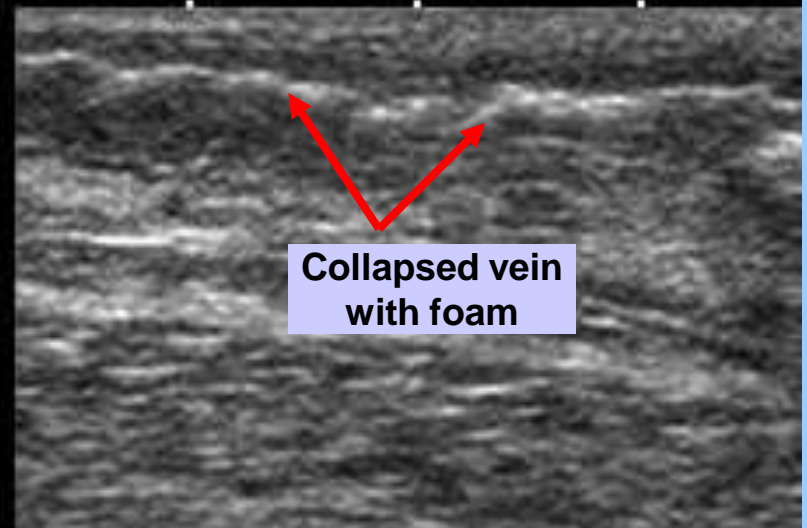
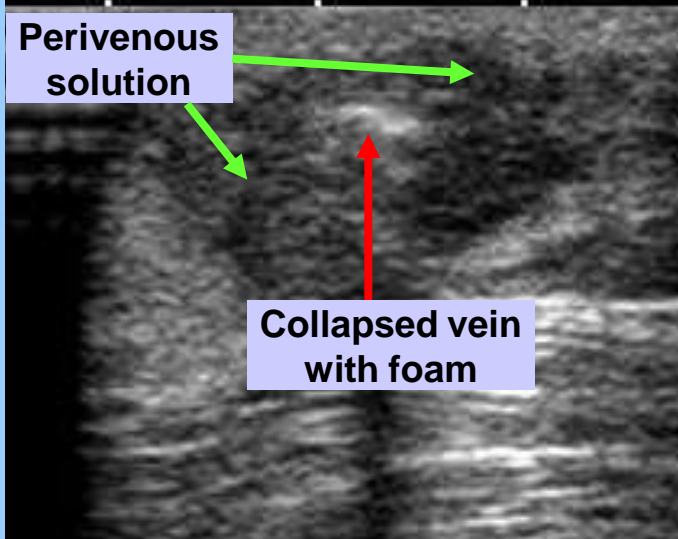
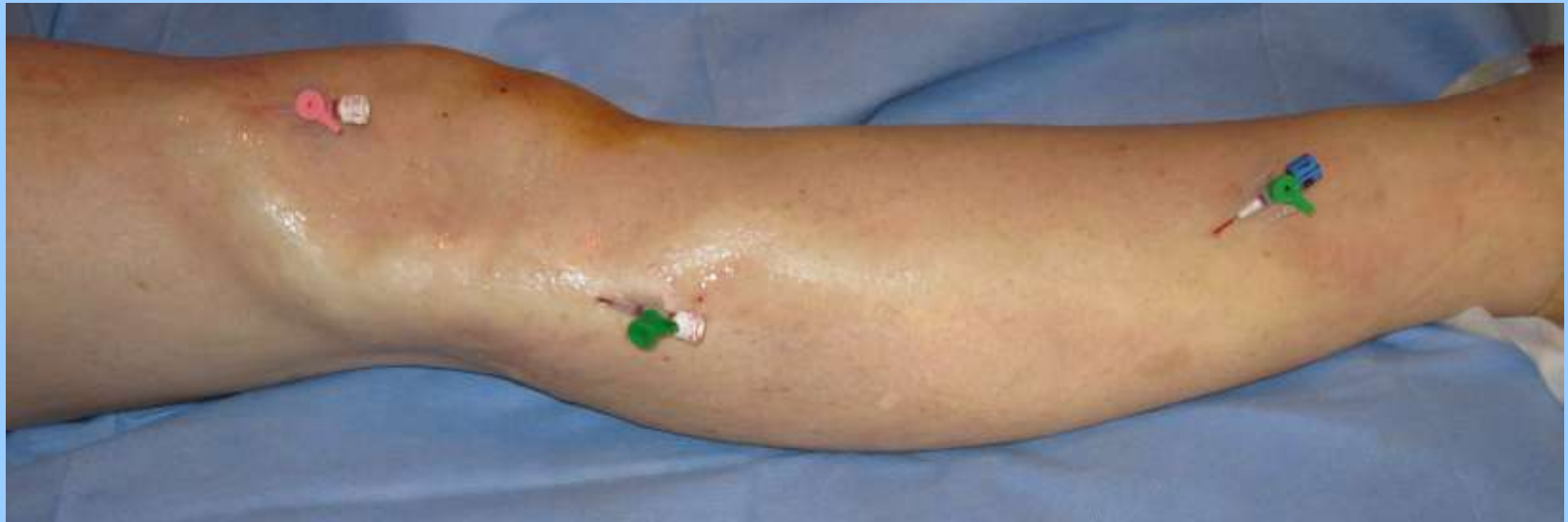In superficial venous insufficiency, after the refluxing truncal or perforating veins are ablated, lower extremity varicose veins are traditionally treated with ambulatory phlebectomy or sclerotherapy (1,2). Although sclerotherapy is more commonly used, large varicose veins are difficult to treat with standard liquid or foam sclerotherapy since they require a higher sclerosant dose and concentration, and the complication rate may be higher due to presence of excessive blood in the vein lumen (2,3). The purpose of our study was to investigate the value of perivenous injection of tumescent solution to increase the effectiveness of ultrasound-guided foam sclerotherapy (US-GFS) for large varicose veins.

## **MATERIALS AND METHODS:**

During a 28 months period, tumescent-augmented sclerotherapy (TAS) was performed in 90 legs in 61 patients (51F, 10M, aged 30-66 years), who had large (1-3cm) varicose veins due to superficial venous insufficiency. On Color Doppler ultrasound (CDUS) examination, there was significant reflux in the great saphenous vein (GSV) in 59 legs, in the small saphenous vein (SSV) in 14 legs, in perforating veins in 5 legs and in multiple veins in 12 legs.

After an informed consent was obtained, first, the incompetent truncal and/or perforating veins were ablated with endovenous laser (ELA) in the standard fashion as described before (3,4). After all the ELA procedures were finished, the patient was put in the reverse Trendelenburg position on the table. Under US guidance, multiple butterfly needles or angiocaths were placed into the remaining large varicose veins. The patient was then put into a slight Trendelenburg position and the tumescent solution used during the ELA was injected under US guidance into the perivenous space around these veins.

# TAS in a patient with large varicose veins due to combined GSV and pelvic vein insufficiency



## **MATERIALS AND METHODS:**

Injections were ended when the veins were totally collapsed. Then, a 3% Polidocanol foam was injected via each needle or angiocath under US guidance. Injections were stopped when extravasation or significant passage into the deep veins were seen on US.

After the ELA and US-GFS, Class II compression stockings were applied and the patient was instructed to walk about 20 minutes. When necessary, ace wraps were also applied around the thigh and groin. Patients were advised to wear compression stockings for at least 1 month and avoid sun light for at least 2 weeks.

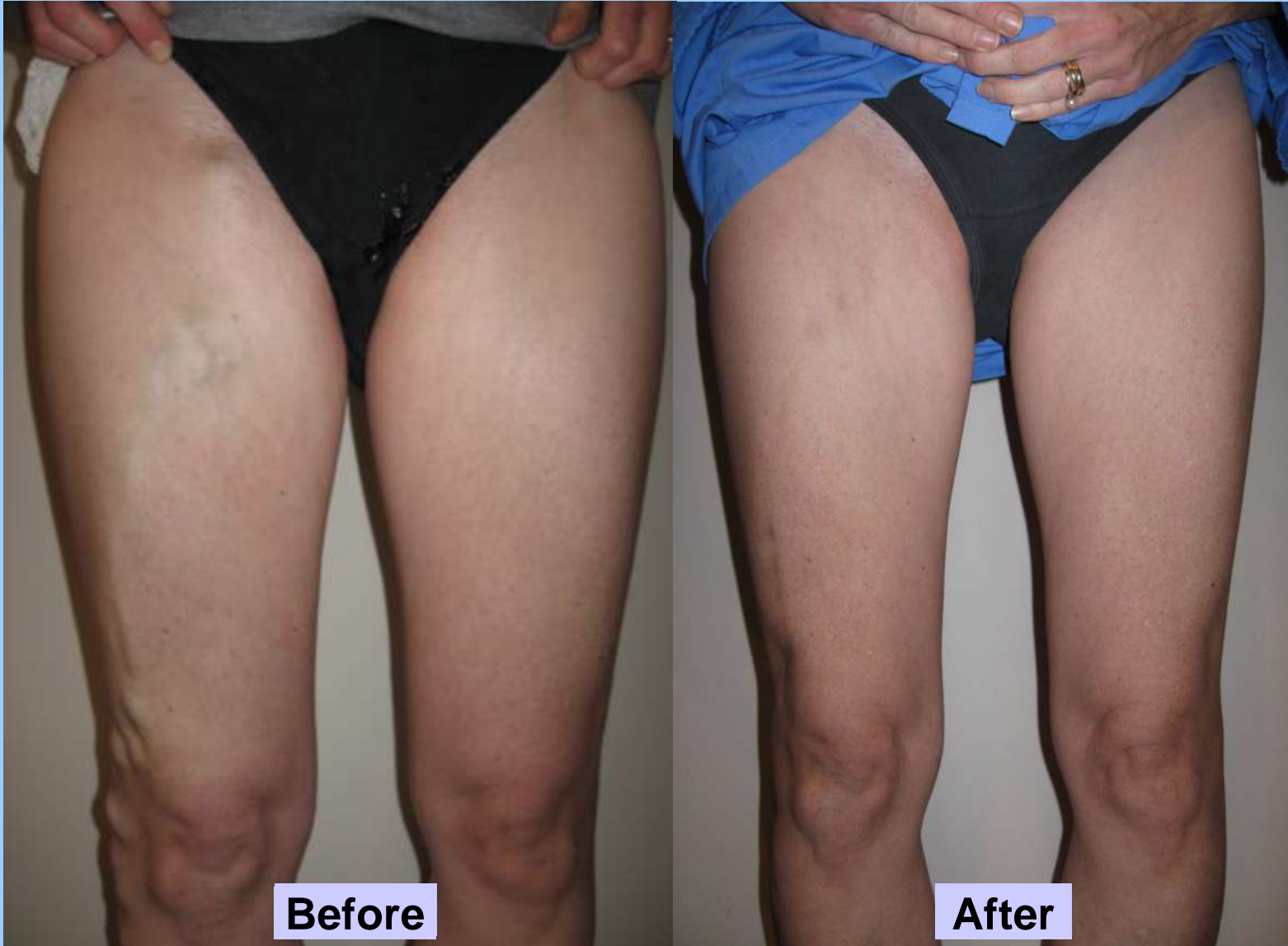All patients were followed up clinically and with color Doppler ultrasound at 1, 3, 6 and 12 months. When reflux was seen in the varicose veins, additional US-GFS was performed.

## **RESULTS:**

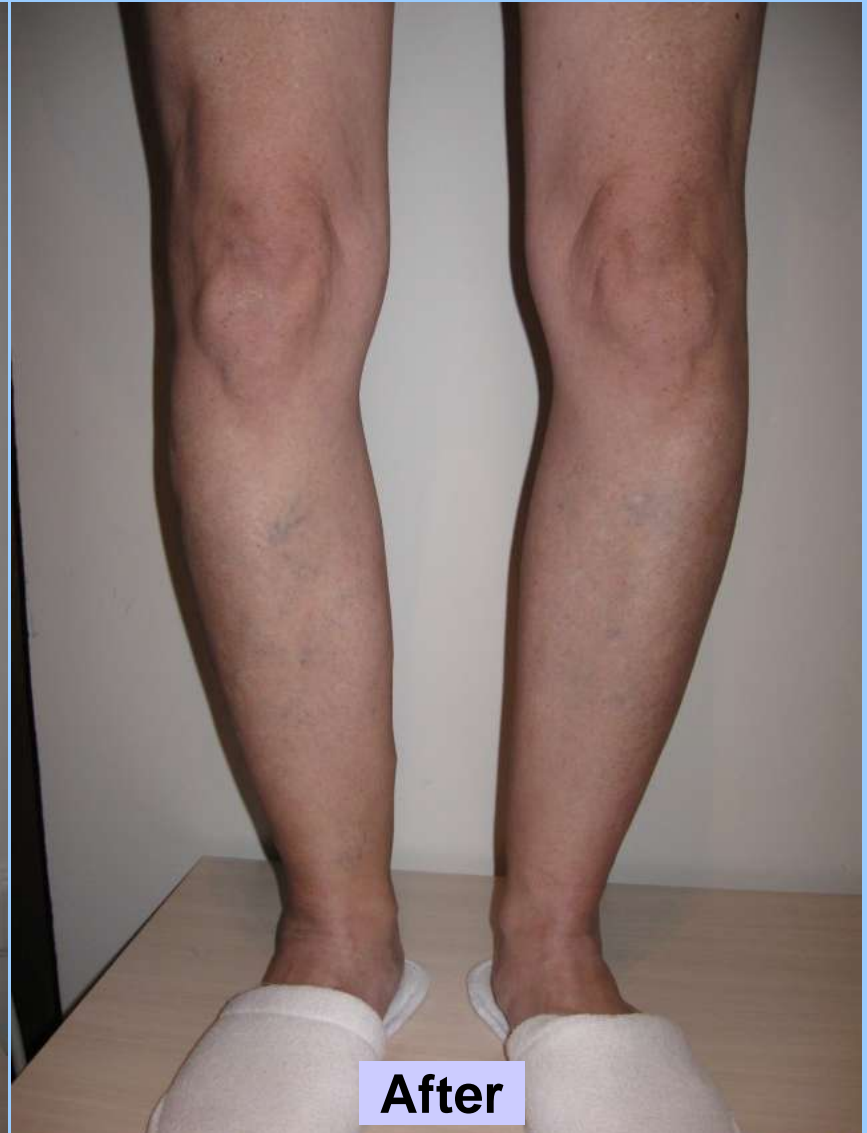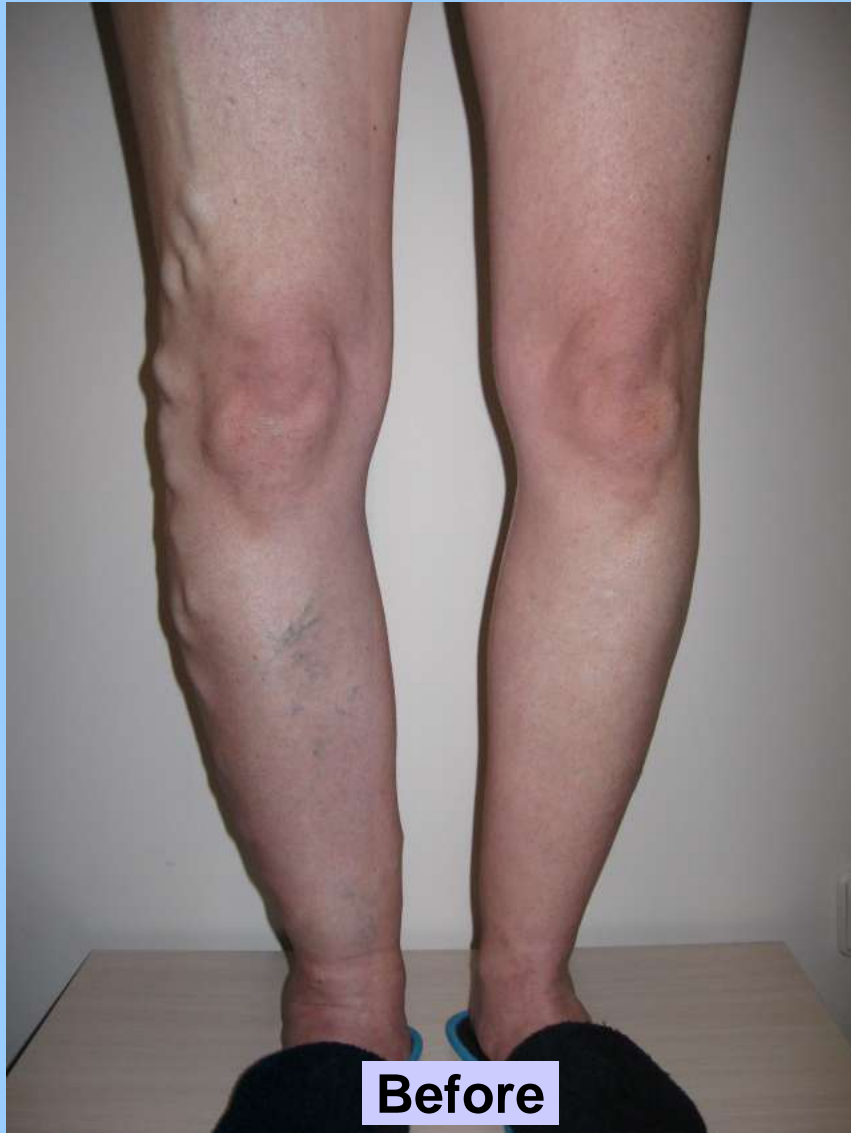TAS and ELA were technically successful in all cases. In 74 legs, one ELA and TAS session was performed while in 16 legs, a second US-GFS session was necessary. Complications included transient hyperpigmentation (42 legs) and skin necrosis (1 leg). Hyperpigmentation was relatively mild and transient, considering the very large diameter of the treated varicose veins. Similarly, postoperative pain and tenderness were minimal in all cases.

During the follow-up (2-27 months), 87 legs were free from reflux on CDUS. In these, a significant clinical and cosmetic improvement was also noted. On CDUS, recanalization was seen in 3 legs with very large (2-3cm) varicosities due to recurrent truncal vein reflux, and successfully treated with US-GFS.

# Cosmetic improvement of the same patient 9 months after ELA and TAS (upper leg)



## Appearance of the same patient (lower leg)





## **CONCLUSIONS:**

In patients with superficial lower extremity venous insufficiency, after the incompetent truncal or perforating veins were ablated with ELA, the remaining varicose veins are treated with ambulatory phlebectomy (AP), sclerotherapy or both (1,2). Large varicose veins are generally removed with AP since it is believed that sclerotherapy alone will not be sufficient (2,5).

However, AP has some disadvantages: First, it is a surgical procedure that requires special surgical instruments which is not very suitable in the office setting. Second, it is a time consuming treatment and most interventional radiologists are not familiar with this technique. Third, although large varicose veins can be successfully removed, small reticular and spider veins remain after AP and these veins should be treated with sclerotherapy (5,6). And fourth, the idea of their veins “removed with hooks” is not welcome by many patients.

## **CONCLUSIONS:**

In the last decade, foam sclerotherapy was introduced and has been extensively used in the treatment of large varicose veins. Foam sclerotherapy has certain advantages over liquid sclerotherapy. First, since liquid mixes instantly with the blood, its concentration drops and its ablative effect diminishes rapidly. On the contrary, foam pushes the blood, rather than mixing with it, and keeps its concentration for a long distance in the vein lumen. As a result, its ablative effect is several times stronger than the liquid, and for this reason, it is suitable for the treatment of large varicose veins. Second, because it is mixed with air, it contains less drug, although it becomes more effective. As a result, it requires less sclerosant and less injection to obtain a certain ablative effect. And third, foam is readily visible on ultrasound, and because it is lighter than blood, it can be easily directed into the target vessels by manual massage and by putting the leg in certain positions (3,7,8).

## **CONCLUSIONS:**

Despite these advantages, foam sclerotherapy may have some drawbacks in very large (1-3cm in diameter) varicose veins. Because of their large size, these veins create more thrombophlebitic symptoms, shrink more slowly and because of the excessive intraluminal blood, create more hyperpigmentation after the sclerotherapy (5,6).

To overcome these drawbacks, we started a new technique which we call “tumescent augmented sclerotherapy” (TAS) for the treatment of very large (1-3cm) varicose veins. In this technique, we injected the standart tumescent solution into the perivenous space until the varicose veins were collapsed, emptying their blood and decreasing their size. We believe that this technique may provide several advantages: first, the foam will be more effective to the vein wall since its concentration is not diluted with the blood. Second, the amount of polidocanol foam will be reduced and this may decrease its side effects. And third, since the tumescent solution will stay in the perivenous space for some hours after the treatment, it will provide an additional compression besides the stockings, which may improve the results of the sclerotherapy.

## **CONCLUSIONS:**

In our study, we have observed these advantages of TAS; in our patients, we ablated the veins using minimum amount of foam and in most, only one session was enough to obtain a durable ablation. After the US-GFS, hyperpigmentation was relatively less despite the large size of the vessels. However, these observations are subjective, and it is necessary to prove our findings with objective measures.

Despite the good results in our study, AF may still be the preferred treatment for such large varicose veins. However, for physicians who do not wish or are not familiar with AF (like most IRs), or for patients who refuse this procedure, TAS may be a good alternative.

In conclusion, TAS may be highly safe and effective in the treatment of large varicosities. By reducing the vein size and emptying its blood content, it may increase the effectiveness and decrease the complication rate of standart US-GFS and provide a good alternative to AF.

## REFERENCES:

1. Leopardi D, Hoggan BL, Fitridge RA, Woodruff PW, Maddern GJ. Systematic review of treatments for varicose veins. *Ann Vasc Surg.* 2009; 23(2): 264-276.
2. Mowatt-Larssen E. Management of secondary varicosities. *Semin Vasc Surg.* 2010; 23(2): 107-112.
3. Yilmaz S, Ceken K, Alparslan A, Sindel T, Lüleci E. Endovenous laser ablation for saphenous vein insufficiency: immediate and short-term results of our first 60 procedures. *Diagn Interv Radiol.* 2007; 13:156-163.
4. Min RJ, Khilnani NM. Endovenous laser ablation of varicose veins. *J Cardiovasc Surg.* 2005; 46: 395-405.
5. de Roos KP, Nieman FH, Neumann HA. Ambulatory phlebectomy versus compression sclerotherapy: results of a randomized controlled trial. *Dermatol Surg.* 2003; 29(3): 221-6.
6. Sadick NS. Advances in the treatment of varicose veins: ambulatory phlebectomy, foam sclerotherapy, endovascular laser, and radiofrequency closure. *Adv Dermatol.* 2006; 22: 139-156.
7. Coleridge Smith P. Sclerotherapy and foam sclerotherapy for varicose veins. *Phlebology.* 2009; 24: 260-269.
8. King T, Coulomb G, Goldman A, Sheen V, McWilliams S, Guptan RC. Experience with concomitant ultrasound-guided foam sclerotherapy and endovenous laser treatment in chronic venous disorder and its influence on Health Related Quality of Life: interim analysis of more than 1000 consecutive procedures. *Int Angiol.* 2009; 28: 289-297.